

Central retinal thickness is positively correlated with macular pigment optical density

S.H. Melissa Liew^a, Clare E. Gilbert^b, Tim D. Spector^a, John Mellerio^c, Frederik J. Van Kuijk^d, Stephen Beatty^e, Fred Fitzke^f, John Marshall^g, Christopher J. Hammond^{a,h,*}

^a Twin Research and Genetic Epidemiology Unit, St Thomas' Hospital, London, UK

^b International Centre for Eye Health, London School of Hygiene and Tropical Medicine, University of London, London, UK

^c School of Biosciences, University of Westminster, London, UK

^d Department of Ophthalmology and Visual Sciences, University of Texas Medical Branch, Galveston, TX, USA

^e Department of Chemical and Life Sciences, Waterford Institute of Technology, Waterford, Ireland

^f Institute of Ophthalmology, London, UK

^g Rayne Institute, St Thomas' Hospital, London, UK

^h West Kent Eye Center, Princess Royal University Hospital, Orpington, UK

Received 7 August 2005; accepted in revised form 20 October 2005

Available online 27 December 2005

Abstract

Macular pigment (MP) has been suggested to have a protective role in age-related macular degeneration by reducing the amount of oxidative stress on the retina. MP levels peak at the foveal center, where it is found predominantly in the receptor axon and inner plexiform layers of the retina. The purpose of this study was to investigate the relationship between central retinal thickness and macular pigment optical density in a group of healthy subjects.

We report that macular pigment optical density (MPOD) has a significant and positive relationship with central retinal thickness as measured by optical coherence tomography. The strength of the observed relationship ($r \sim 0.30$) was independent of the technique used to measure MPOD, whether heterochromatic flicker photometry (HFP) or 2-wavelength autofluorescence (AF). Of note, there was no statistically demonstrable relationship between MPOD at an eccentricity of 1- or 2-degrees and central retinal thickness. This finding has important implications for future studies investigating MPOD, and its response to dietary modification/supplementation.

© 2005 Elsevier Ltd. All rights reserved.

Keywords: macular pigment; lutein, carotenoids; retinal thickness; xanthophylls

1. Introduction

Macular pigment (MP) is a blue-light absorbing pigment, which is concentrated in the central macular region. MP is composed of two dietary hydroxy-carotenoids, lutein (L) and zeaxanthin (Z), which form the characteristic yellow spot seen in the central macula region (Bone et al., 1985). L and Z are thought to have a protective effect in the eye by limiting the oxidative stress on the retina through their role as blue-light filters and/or by acting as direct antioxidants (Snodderly et al., 1984a; Khachik et al., 1997; Boulton et al., 2001). As oxidative

stress is likely to play a role in the pathogenesis of ARMD, it has been hypothesized that MP may protect against this condition, which is still the leading cause of blindness in the Western world (Beatty et al., 2000a; Margrain et al., 2004). Several studies have published data, which shows that serum and dietary levels of L and Z are inversely associated with risk for advanced ARMD (Seddon et al., 1994; Beatty et al., 2001; Gale et al., 2003) stimulating interest in the potential protective effect of augmenting MP levels through supplementation or dietary modification. So far, studies suggest that although serum levels of lutein generally increase above baseline with supplementation or dietary modification, the MPOD response is less predictable, reflected in the considerable variability in the magnitude of the MPOD increase, with some individuals failing to demonstrate any rise in MPOD despite high amounts of supplementation (Hammond et al., 1997a; Landrum et al., 1997; Johnson et al., 2000). Foveal architecture has been postulated to contribute to the variation in MP levels in humans

* Corresponding author. Address: Christopher J. Hammond, Twin Research and Genetic Epidemiology Unit, St Thomas' Hospital, Lambeth palace road, London SE1 7EH, UK.

E-mail address: chammond@btopenworld.com (C.J. Hammond).

(Hammond et al., 1997b) and MP has been shown to be significantly related to central retinal thickness in several types of retinal degeneration including Usher syndrome, retinitis pigmentosa and choroideremia (Aleman et al., 2001; Duncan et al., 2002).

The spatial distribution of MP has previously been investigated and spectroscopic studies of primate maculae have found the highest concentrations of MP to be in the receptor axon and inner plexiform layers of the retina (Snodderly et al., 1984b). MP concentration peaks at the foveal center, where the highest density of MP is found in the receptor axon layer, but MP density declines rapidly with increasing eccentricity to low, relatively constant levels within 1mm retinal eccentricity (Snodderly et al., 1984a).

Central retinal thickness varies widely among individuals and is now easily measured in the clinic using optical coherence tomography (OCT) (Hee et al., 1995). Numerous studies have shown high reproducibility of retinal thickness measurements using OCT (Massin et al., 2002; Alamouti and Funk, 2003). The purpose of this study was to investigate the relationship between central retinal thickness and MP optical density in healthy individuals.

2. Materials and methods

We measured the macular pigment optical density (MPOD) and central retinal thickness of 322 healthy, female subjects, who were recruited as part of a twin study on MP heritability. All the subjects have been recruited to the TwinsUK adult registry held at St Thomas' Hospital, London, through local and national media campaigns and were subsequently invited to participate in an eye study. An upper age limit was set at 50 years to increase the likelihood of recruiting subjects with healthy retinas. Research procedures followed the tenets of the Declaration of Helsinki and were approved by the local ethics committee.

An ocular history and examination was performed on all subjects to exclude subjects with any previous ocular surgery or retinal pathology (including early age related maculopathy). Retinal thickness and MPOD were measured in the same session, by a single investigator. Retinal thickness was measured using OCT (Stratus model 3000; Carl Zeiss), following pupil dilation with 1% tropicamide. Six radial scans (6 mm long), centred on the fixation point, were performed on each eye. Using OCT, the retinal thickness is calculated as the distance between the vitreoretinal interface and the retinal pigment epithelium (RPE). Retinal thickness was calculated automatically using the in built topographic mapping software. For each eye, a single retinal map was acquired using all six scans, centred on the subject's fixation point. In order to investigate the relationship between MP and retinal thickness, we used the average retinal thickness value in the central 1000 μm ($\sim 3.3^\circ$) diameter zone (A1), as optically detectable levels of the pigment are found within this area. We also recorded the central foveal thickness (average retinal thickness at point of intersection of the six radial scans), because MP peaks at this location. OCT measurements were

performed in 308 volunteers, but the results from three subjects were excluded due to high refractive error compromising image quality. Retinal thickness was therefore measured in 612 eyes (305 right eyes, 307 left eyes).

MPOD was measured using a psychophysical (heterochromatic flicker photometry [HFP]) and by an objective, image-based technique (2-wavelength, autofluorescence [AF]). As each of these methods use different underlying assumptions to estimate MPOD *in vivo*, we used both techniques to investigate whether their respective relationships with retinal thickness would be comparable.

2.1. Psychophysical technique

A portable HFP device (called a Maculometer) was employed (Mellerio et al., 2002). The Maculometer uses a 1-degree foveal test field and a parafoveal test field consisting of an annulus of 10-degrees diameter. HFP uses MP's spectral and anatomical properties; MP absorbs strongly in the blue portion of the spectrum, thereby attenuating the spectral sensitivity of macular photoreceptors to blue light. During this test, the subject fixes on a central test field which flickers between blue [$I_{\text{max}} = 468$ nm, close to the maximum absorption wavelength of MP], and green [$I_{\text{max}} = 535$ nm, corresponding to minimum absorption by the MP]. The subject varies the luminance of the blue light until the perception of flicker is minimized, and then repeats the task with the test field imaged in the parafovea, where MP is assumed to be negligible. The MP density at the test wavelength is therefore given by $\log(I_{\text{foveal}}/I_{\text{parafoveal}})$ where I_{foveal} is the luminance of the blue light for minimum flicker in the fovea and $I_{\text{parafoveal}}$ is the luminance of the blue light for minimum flicker in the parafovea.

2.2. Image-based technique

AF images were acquired using a modified confocal scanning laser ophthalmoscope (Heidelberg Engineering, Heidelberg). Delori et al developed this method of MPOD measurement, which takes advantage of the AF of retinal pigment epithelium (RPE) lipofuscin. Lipofuscin is excited *in vivo* by wavelengths of light between 400–570 nm (Delori et al., 1995; Delori, 2004). Two wavelengths of light are used to stimulate AF, one that is well absorbed by MP (488 nm) and one that is minimally absorbed by MP (514 nm), to allow quantification of MP density. It is assumed that MP is the major component responsible for the attenuation of AF in the central macula. A common barrier filter (530 nm) was used so that the intensity of emitted AF was measured near the threshold where MP has no absorption, enabling a single-pass measurement of MP density. A software programme has been developed to quantify MPOD, which generates maps by digital subtraction of the AF images taken at the two different wavelengths and uses a gray scale index of intensity (Wustemeyer et al., 2003). In this study, we evaluated the peak MPOD (foveal centre/0-degrees eccentricity), the MPOD at half-degree, 1-degree and 2-degrees eccentricity from the foveal center and also the

average MPOD in the central 1, 2 and 4-degree diameter area (centred on the fovea).

The computer statistics package, STATA (Version 8 SE Stata Corporation), was used for data analysis and statistics.

3. Results

The mean (\pm SD) logMAR visual acuity of all included subjects was 0.0 ± 0.1 . The mean central retinal thickness (central 1000 μm diameter area) was 212 μm (SD: 19; range: 165–277) and revealed a normal distribution (skew test, $p=0.22$) (Fig. 1). Mean central retinal thickness exhibited a high degree of inter-ocular symmetry, represented by a correlation coefficient of 0.91 between subjects' fellow eyes. The mean central foveal retinal thickness was 178 μm (SD: 23; range: 127–252), and this also exhibited a high degree of inter-ocular agreement ($r=0.84$), and a normal distribution pattern (skew test, $p=0.27$).

Using HFP, the mean MPOD value was 0.44 (range -0.06 to 1.25). When right and left eyes were analyzed separately, the mean MPOD value was the same for both eyes (right eye: mean 0.44, SD 0.21; range 0.004–1.25; left eye: mean 0.44, SD 0.19; range -0.06 to 1.09) and the inter-ocular correlation coefficient between subjects' fellow eyes was 0.81. MP readings from 11 subjects were excluded due to poor fixation or difficulty in performing the test.

Using the AF method, the mean (\pm SD) peak MPOD was 0.71 ± 0.20 (range 0.24–1.21). The mean MPOD measured at half-degree, 1-degree and 2-degrees eccentricity was 0.41 ± 0.15 (0.03–0.96), 0.28 ± 0.11 (0.01–0.73) and 0.09 ± 0.04 (0–0.27), respectively. The mean MPOD in the central 1-degree, 2-degree and 4-degree diameter zone was 0.51 ± 0.16 (0.1–1.05), 0.38 ± 0.13 (0.04–0.86) and 0.21 ± 0.08 (0.04–0.54), respectively. There was a very high degree of inter-ocular symmetry, with intraclass correlations of between 0.91 and 0.97, for all the AF measurements evaluated.

As there was a high inter-ocular correlation in retinal thickness and MPOD measurements, the mean value for both

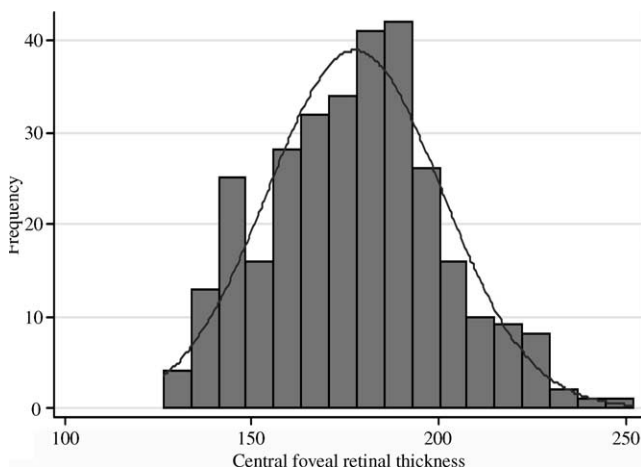


Fig. 1. Frequency distribution of central foveal retinal thickness, measured by optical coherence tomography.

eyes, of each individual, was used to investigate the relationship between these two parameters. Using HFP, MPOD values were positively and significantly related with mean central retinal thickness and with central foveal thickness (no. observations=296), represented by comparable correlation coefficients of 0.29 and 0.28, respectively ($p<0.0001$) (Fig. 2(a)).

Using AF, MPOD values measured within the central one-degree diameter also correlated positively and significantly with mean central retinal and foveal thicknesses (no. observations=306), represented by correlation coefficients of between 0.26 and 0.40 ($p<0.0001$). Correlation results are detailed in Table 1. The highest correlation was found between the average MPOD in the central 1-degree area and foveal retinal thickness, with a coefficient (r) of 0.40 (Fig. 2(b)). Fig. 3 shows the retinal thickness and MPOD profiles of 2 subjects, one with low central retinal thickness and low MPOD and one with high retinal thickness and high MPOD. There was no statistically demonstrable relationship between retinal thickness and the AF MPOD measured at 1-degree eccentricity, 2-degree eccentricity or the mean MPOD in the central 4-degrees.

To account for any sibling relationship, as our subject population included twin pairs, the relationship between MPOD and retinal thickness was re-analyzed using one twin chosen at random from each pair. We found the same positive

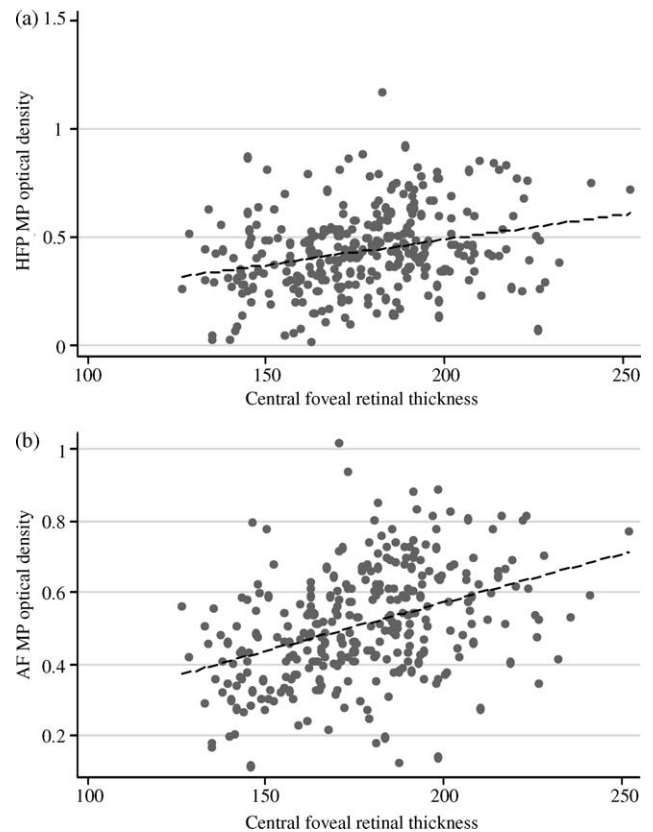


Fig. 2. Relationship of macular pigment optical density (MPOD) and foveal retinal thickness (measured by OCT). (a) MPOD measured by heterochromatic flicker photometry (HFP) ($r=0.28$). (b) Peak MPOD measured by autofluorescence (AF) ($r=0.33$).

Table 1
Summary of retinal thickness and macular pigment optical density correlations

	MRT	FRT
HFP	0.29, $p < 0.0001$	0.28, $p < 0.0001$
AF-peak	0.29, $p < 0.0001$	0.33, $p < 0.0001$
AF-central 1° area	0.33, $p < 0.0001$	0.40, $p < 0.0001$
AF-0.5° eccentricity	0.26, $p < 0.0001$	0.32, $p < 0.001$
AF-central 2° area	0.13, $p = 0.02$	0.19, $p = 0.001$
AF-1° eccentricity	-0.09	-0.05
AF-central 4° area	-0.01	0.01
AF-2° eccentricity	-0.04	-0.09

Abbreviations: MRT, macular retinal thickness (average retinal thickness in central 1000 μm area); FRT, foveal retinal thickness; HFP, heterochromatic flicker photometry macular pigment measurements; AF, autofluorescence macular pigment measurements. (P values are given only if the relationship is statistically significant).

relationship, of the same magnitude ($r \sim 0.30$), using AF MPOD and HFP MPOD readings with respect to measures of macular and foveal retinal thickness.

4. Discussion

In recent years, there has been a growing level of interest in the effects of dietary modification and supplementation on MPOD, primarily because of the possible protection that this pigment may confer against ARMD. However studies have shown large variations in the response of MPOD to supplementation or dietary modification (Hammond et al., 1997(a); Landrum et al., 1997). Therefore it is likely that other factors, genetic and or environmental, influence an individual's

response to supplementation. To our knowledge, this is the largest study examining the relationship of MPOD and retinal thickness in healthy subjects.

In this study, we have measured MPOD and retinal thickness in 306 healthy subjects to examine the relationship between these two parameters. The mean MPOD of this study group, measured using HFP, was 0.44 and is comparable to other studies where a similar sized central test field was used, including Beatty et al.'s study (mean 0.496; t -test, $p = 0.32$), Mellerio et al.'s study (mean 0.41; t -test, $p = 0.12$) and Werner et al.'s study (mean 0.39) (Werner et al., 1987; Beatty et al., 2000b; Mellerio et al., 2002). Our AF measurements of the average MPOD in the central 2-degree diameter area (0.38 ± 0.13) are comparable with Delori et al's AF results which reported a mean of 0.37 ± 0.12 (Delori et al., 2001) (t -test, $p = 0.41$). However a study by Wustemeyer et al, performed using a similar HRA apparatus, reported a lower mean MPOD averaged in a central two degree area (0.22 ± 0.07) (Wustemeyer et al., 2003).

The mean foveal retinal thickness in this study (178 ± 23) is comparable to the normal subject group in Aleman et al's study which reported a mean foveal retinal thickness of 170 ± 14.7 (t -test, $p = 0.22$) (Aleman et al., 2001). The mean central retinal thickness in this study group was $212 \mu\text{m}$ (SD 19) which is similar to a previous study examining healthy eyes using OCT which reported a mean value of 209 ± 20.5 (t -test, $p = 0.40$) (Guedes et al., 2003). A study by Lim et al has found the mean central retinal thickness of healthy subjects to be higher ($231 \pm 10.5 \mu\text{m}$) in a Singapore population (Lim et al., 2005).

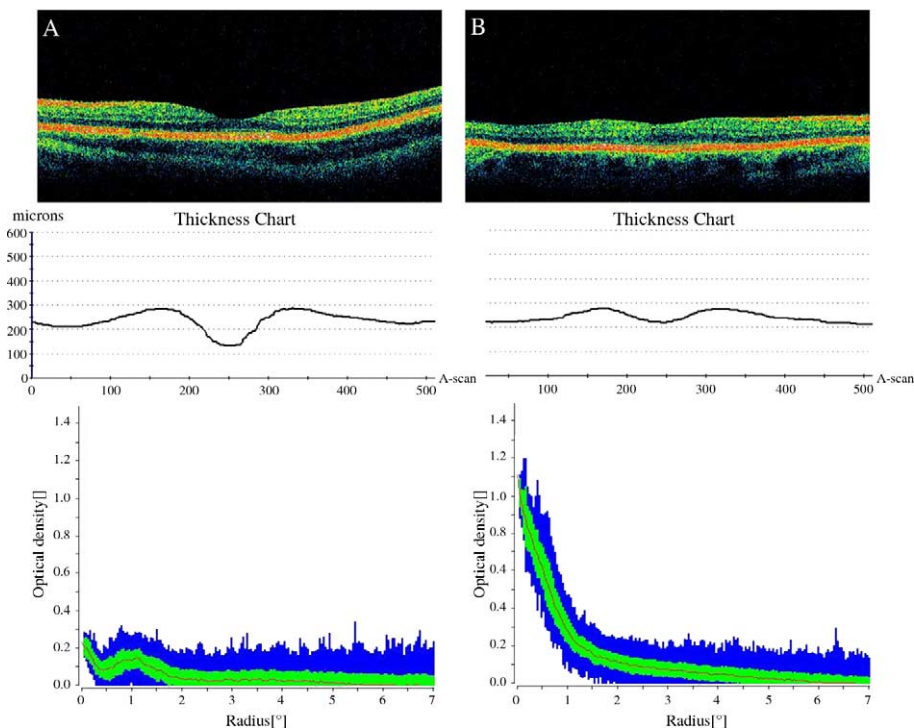


Fig. 3. OCT images (top row), retinal thickness profiles generated by OCT software (middle row) and macular pigment optical density (MPOD) profiles (bottom row) generated by autofluorescence, for 2 subjects. Subject A (left column images) has a thin foveal retinal thickness of $135.0 \mu\text{m}$ and a low MPOD of 0.03 and 0.17 measured by heterochromatic flicker photometry and autofluorescence (mean MPOD in central 1-degree area), respectively. Subject B has a high foveal retinal thickness of $222.5 \mu\text{m}$ and a high MPOD of 0.68 and 0.8 measured by heterochromatic flicker photometry and autofluorescence, respectively.

As our MPOD and macular retinal thickness readings are comparable to other studies and because twins have been shown to be comparable to singletons in many complex traits (Andrew et al., 2001), we believe the results of this study are generalisable to healthy subjects aged 17–50 years of age.

Previous studies have found that MPOD in patients with retinal degeneration (choroideremia, retinitis pigmentosa, usher syndrome) is significantly and inversely related to retinal thickness ($r=0.57/0.66$) (Aleman et al., 2001; Duncan et al., 2002), suggesting that loss of retinal tissue may influence MP levels. Duncan et al. assessed whether foveal thickness influences response to lutein supplementation in patients with choroideremia. The results did not show a statistically significant difference in the mean foveal thickness of responders compared with non-responders however the size of this study was very small with only seven subjects receiving lutein supplementation (Duncan et al., 2002). Interestingly, Aleman et al. found that retinal non-responders to supplementation had greater severity of retinitis pigmentosa or Usher syndrome. We can speculate that genetic background may influence the retinal response to dietary L and/or Z, and a poor response may increase the risk or severity of retinal degeneration. Indeed, a classical twin study has demonstrated that genetic factors are important determinants of MP levels, with heritability estimates of 0.67–0.85 (Liew et al., 2005).

We have found a significant relationship between central retinal thickness and MPOD, in healthy subjects, in the central 1-degree diameter retinal area, assessed using two very different methods, AF and HFP. The magnitude of the relationship was also very similar ($\sim r=0.30$) using the two different methods of MP assessment. However, the strength of the relationship was modest in this group of healthy subjects, and less than that found in patients with retinal degeneration, suggesting that there is a more complex relationship in retinal tissue that is not diseased (Aleman et al., 2001).

Although significant levels of MP are usually found at 1- and 2-degrees retinal eccentricity, surprisingly, we did not find a significant relationship with retinal thickness at these locations. MPOD distribution profiles vary considerably between different individuals. Observing the MPOD profile from the periphery to the foveal center, some individuals exhibit a central depression or dip in MPOD before reaching the peak level, as shown in Fig. 3 (subject A) (Hammond et al., 1997b; Snodderly et al., 1984a; Aleman et al., 2001; Robson et al., 2003). It is possible that the central depression in MPOD may be related to physiological thinning at the fovea. Therefore, a deeper foveal dip in retinal thickness may be associated with a more marked reduction in MPOD. Subject A in Fig. 3 shows a deep foveal pit on OCT and also has a marked central depression in MPOD, demonstrated by the AF MPOD profile. In comparison, subject B in Fig. 3 has a shallower foveal pit and the MPOD profile does not show a central depression but levels rise steadily to reach a peak. It can be postulated that the amount of retinal tissue present may influence the accumulation or storage of MP as our results

suggest a positive linear relationship of MPOD with retinal thickness.

As most of the MP is found at the fovea and decreases approximately exponentially towards the periphery, the foveal thickness may have a more pronounced influence on central MPOD and may explain why this relationship was only detectable in the central region. In this study, the foveal retinal thickness appeared to have higher correlations with MPOD compared to the corresponding macular retinal thickness correlations (Table 1). The peak MPOD and the average MPOD over the central 1-degree disc area, measured by AF, exhibiting the strongest correlations with FRT.

We have shown a significant, but modest ($r^2=0.09$) relationship between central retinal thickness and macular pigment optical density. Future developments in OCT technology will allow further investigation of the relationship between the spatial profile of MP and the layer structure of the retina. Further research may shed light on whether retinal thickness or architecture has important implications regarding response to lutein/zeaxanthin supplementation. In addition, future studies investigating the relationship between MP and ARMD need to consider the relationship between retinal thickness and MP, and even the possibility that a thin retina may be an independent risk factor for ARMD, with the association of ARMD and low MP being secondary to this.

Acknowledgements

We are grateful to all the volunteers. Financial support was provided by the Wellcome Trust. The authors also thank Prof. Miles Stanford for his support of this research and use of the OCT machine.

References

- Alamouti, B., Funk, J., 2003. Retinal thickness decreases with age: an OCT study. *Br. J. Ophthalmol.* 87, 899–901.
- Aleman, T.S., Duncan, J.L., Bieber, M.L., De Castro, E., Marks, D.A., Gardner, L.M., Steinberg, J.D., Cideciyan, A.V., Maguire, M.G., Jacobson, S.G., 2001. Macular pigment and lutein supplementation in retinitis pigmentosa and Usher syndrome. *Invest. Ophthalmol. Vis. Sci.* 42, 1873–1881.
- Andrew, T., Hart, D.J., Snieder, H., de Lange, M., Spector, T.D., MacGregor, A.J., 2001. Are twins and singletons comparable? A study of disease-related and lifestyle characteristics in adult women. *Twin Res.* 4, 464–477.
- Beatty, S., Koh, H., Phil, M., Henson, D., Boulton, M., 2000a. The role of oxidative stress in the pathogenesis of age-related macular degeneration. *Surv. Ophthalmol.* 45, 115–134.
- Beatty, S., Koh, H.H., Carden, D., Murray, I.J., 2000b. Macular pigment optical density measurement: a novel compact instrument. *Ophthalmic Physiol. Opt.* 20, 105–111.
- Beatty, S., Murray, I.J., Henson, D.B., Carden, D., Koh, H., Boulton, M.E., 2001. Macular pigment and risk for age-related macular degeneration in subjects from a Northern European population. *Invest. Ophthalmol. Vis. Sci.* 42, 439–446.
- Bone, R.A., Landrum, J.T., Tarsis, S.L., 1985. Preliminary identification of the human macular pigment. *Vision Res.* 25, 1531–1535.
- Boulton, M., Rozanowska, M., Rozanowski, B., 2001. Retinal photodamage. *J. Photochem. Photobiol. B* 64, 144–161.

- Delori, F.C., 2004. Autofluorescence method to measure macular pigment optical densities fluorometry and autofluorescence imaging. *Arch. Biochem. Biophys.* 430, 156–162.
- Delori, F.C., Dorey, C.K., Staurenghi, G., Arend, O., Goger, D.G., Weiter, J.J., 1995. In vivo fluorescence of the ocular fundus exhibits retinal pigment epithelium lipofuscin characteristics. *Invest. Ophthalmol. Vis. Sci.* 36, 718–729.
- Delori, F.C., Goger, D.G., Hammond, B.R., Snodderly, D.M., Burns, S.A., 2001. Macular pigment density measured by autofluorescence spectrometry: comparison with reflectometry and heterochromatic flicker photometry. *J. Opt. Soc. Am. A Opt. Image Sci. Vis.* 18, 1212–1230.
- Duncan, J.L., Aleman, T.S., Gardner, L.M., De Castro, E., Marks, D.A., Emmons, J.M., Bieber, M.L., Steinberg, J.D., Bennett, J., Stone, E.M., MacDonald, I.M., Cideciyan, A.V., Maguire, M.G., Jacobson, S.G., 2002. Macular pigment and lutein supplementation in choroideremia. *Exp. Eye Res.* 74, 371–381.
- Gale, C.R., Hall, N.F., Phillips, D.I., Martyn, C.N., 2003. Lutein and zeaxanthin status and risk of age-related macular degeneration. *Invest. Ophthalmol. Vis. Sci.* 44, 2461–2465.
- Guedes, V., Schuman, J.S., Hertzmark, E., Wollstein, G., Correnti, A., Mancini, R., Lederer, D., Voskanyan, S., Velazquez, L., Pakter, H.M., Pedut-Kloizman, T., Fujimoto, J.G., Mattox, C., 2003. Optical coherence tomography measurement of macular and nerve fiber layer thickness in normal and glaucomatous human eyes. *Ophthalmology* 110, 177–189.
- Hammond Jr., B.R., Johnson, E.J., Russell, R.M., Krinsky, N.I., Yeum, K.J., Edwards, R.B., Snodderly, D.M., 1997a. Dietary modification of human macular pigment density. *Invest. Ophthalmol. Vis. Sci.* 38, 1795–1801.
- Hammond Jr., B.R., Wooten, B.R., Snodderly, D.M., 1997b. Individual variations in the spatial profile of human macular pigment. *J. Opt. Soc. Am. A Opt. Image Sci. Vis.* 14, 1187–1196.
- Hee, M.R., Izatt, J.A., Swanson, E.A., Huang, D., Schuman, J.S., Lin, C.P., Puliafito, C.A., Fujimoto, J.G., 1995. Optical coherence tomography of the human retina. *Arch. Ophthalmol.* 113, 325–332.
- Johnson, E.J., Hammond, B.R., Yeum, K.J., Qin, J., Wang, X.D., Castaneda, C., Snodderly, D.M., Russell, R.M., 2000. Relation among serum and tissue concentrations of lutein and zeaxanthin and macular pigment density. *Am. J. Clin. Nutr.* 71, 1555–1562.
- Khachik, F., Bernstein, P.S., Garland, D.L., 1997. Identification of lutein and zeaxanthin oxidation products in human and monkey retinas. *Invest. Ophthalmol. Vis. Sci.* 38, 1802–1811.
- Landrum, J.T., Bone, R.A., Joa, H., Kilburn, M.D., Moore, L.L., Sprague, K.E., 1997. A one year study of the macular pigment: the effect of 140 days of a lutein supplement. *Exp. Eye Res.* 65, 57–62.
- Liew, S.H.M., Gilbert, C.E., Spector, T.D., Mellerio, J., Marshall, J., van kuijk, F.J., Beatty, S., Fitzke, F., Hammond, C.J., 2005. Heritability of macular pigment: a twin study. *Invest. Ophthalmol. Vis. Sci.* 46, 4430–4436.
- Lim, M.C., Hoh, S.T., Foster, P.J., Lim, T.H., Chew, S.J., Seah, S.K., Aung, T., 2005. Use of optical coherence tomography to assess variations in macular retinal thickness in myopia. *Invest. Ophthalmol. Vis. Sci.* 46, 974–978.
- Margrain, T.H., Boulton, M., Marshall, J., Sliney, D.H., 2004. Do blue light filters confer protection against age-related macular degeneration? *Prog. Retin. Eye Res.* 23, 523–531.
- Massin, P., Erginay, A., Haouchine, B., Mehidi, A.B., Paques, M., Gaudric, A., 2002. Retinal thickness in healthy and diabetic subjects measured using optical coherence tomography mapping software. *Eur. J. Ophthalmol.* 12, 102–108.
- Mellerio, J., Ahmadi-Lari, S., van Kujik, F., Pauleikhoff, D., Bird, A., Marshall, J., 2002. A portable instrument for measuring macular pigment with central fixation. *Curr. Eye Res.* 25, 37–47.
- Robson, A.G., Moreland, J.D., Pauleikhoff, D., Morrissey, T., Holder, G.E., Fitzke, F.W., Bird, A.C., van Kujik, F.J., 2003. Macular pigment density and distribution: comparison of fundus autofluorescence with minimum motion photometry. *Vision Res.* 43, 1765–1775.
- Seddon, J.M., Ajani, U.A., Sperduto, R.D., Hiller, R., Blair, N., Burton, T.C., Farber, M.D., Gragoudas, E.S., Haller, J., Miller, D.T., 1994. Dietary carotenoids, vitamins A, C, and E, and advanced age-related macular degeneration. Eye disease case-control study group. *J. Am. Med. Assoc.* 272, 1413–1420.
- Snodderly, D.M., Auran, J.D., Delori, F.C., 1984a. The macular pigment. II. Spatial distribution in primate retinas. *Invest. Ophthalmol. Vis. Sci.* 25, 674–685.
- Snodderly, D.M., Brown, P.K., Delori, F.C., Auran, J.D., 1984b. The macular pigment. I. Absorbance spectra, localization, and discrimination from other yellow pigments in primate retinas. *Invest. Ophthalmol. Vis. Sci.* 25, 660–673.
- Werner, J.S., Donnelly, S.K., Kliegl, R., 1987. Aging and human macular pigment density. Appended with translations from the work of Max Schultze and Ewald Hering. *Vis. Res.* 27, 257–268.
- Wustemeyer, H., Moessner, A., Jahn, C., Wolf, S., 2003. Macular pigment density in healthy subjects quantified with a modified confocal scanning laser ophthalmoscope. *Graefes Arch. Clin. Exp. Ophthalmol.* 241, 647–651.